JAUA
Journal of Academic Union Association

IMMUNOHİSTOCHEMİCAL EXAMİNATİON OF HSP-27 EXPRESSİON IN THE LUNGS OF SHEEP WİTH BRONCOPNEUMONİA

Bayram BEKMEZ[1,a], Musab BÜRKEK[1,b,✉], Mehmet Şevki ÇADIRCI[2,c], Muhammet Bahaeddin DÖRTBUDAK[1,d]

[1.] Harran University, Faculty of Veterinary Medicine, Department of Pathology. 63000, Şanlıurfa, Turkey

[2.] Harran University, Institute of Health Sciences, 63000, Şanlıurfa, Turkey

[a.] https://orcid.org/0009-0008-1147-3918, bekmezbayram107@gmail.com

[b.] https://orcid.org/0009-0002-3529-5374, musabuniversite97@gmail.com

[c.] https://orcid.org/0000-0002-6311-7578, msevkic@hotmail.com

[d.] https://orcid.org/0000-0001-5777-964X, mbdortbudak@gmail.com

✉**Corresponding author:** musabuniversite97@gmail.com, +90 541 975 12 31

**This study was presented as an oral/abstract presentation at the "MEETCON-WORK INTERNATİONAL CONGRESS ON FOOD, AGRİCULTURE, AND VETERİNARY SCİENCES".*

ABSTRACT

Respiratory diseases in sheep, which form a significant part of the livestock sector, represent a serious problem. The aim of this study was to investigate the presence of oxidative stress in the pathogenesis of bronchopneumonia, one of the most commonly observed lung diseases in sheep. To this end, the expression of HSP (heat shock protein) 27, a current biomarker of oxidative stress, was monitored in lung tissue samples from sheep with bronchopneumonia. The study material consisted of lung tissues from 16 sheep of different breeds, ages and sexes. Haematoxylin-Eosin (HE) staining was performed for histopathology, and immunohistochemical staining was carried out to examine HSP 27 expression in lung tissues exhibiting macroscopic findings consistent with bronchopneumonia (consolidation). Histopathological examination revealed fibrinous inflammatory cell exudation in the bronchi/bronchioles and alveolar lumina, as well as degeneration, necrosis and vascular changes in the respiratory tract epithelia. In the immunohistochemical examination, HSP 27 expression was observed in the bronchi/bronchioles and alveolar epithelia, as well as in inflammatory cells. The results of this study demonstrated that oxidative stress, which plays a role in the pathogenesis of many diseases, is also relevant in sheep bronchopneumonia, as evidenced by the expression of HSP 27, an important biomarker of oxidative stress. Furthermore, it was concluded that HSP 27 may play a potential role in the diagnosis of the disease, in addition to contributing to the pathogenesis of sheep bronchopneumonia.

Key words: Heat shock protein, Oxidative stress, Pathology, Pneumonia, Sheep

JAUA
Journal of Academic Union Association

BRONKOPNÖMONİLI KOYUN AKCİĞERLERİNDE HSP-27 EKSPRESYONUN İMMÜNOHİSTOKİMYAL İNCELENMESİ

Bayram BEKMEZ[1,a], Musab BÜRKEK[1,b,✉], Mehmet Şevki ÇADIRCI[2,c], Muhammet Bahaeddin DÖRTBUDAK[1,d]

[1.] Harran Üniversitesi, Veterinerlik Fakültesi, Patoloji Anabilim Dalı, 63000, Şanlıurfa, Türkiye

[2.] Harran Üniversitesi, Sağlık Bilimleri Enstitüsü, 63000, Şanlıurfa, Türkiye

[a]. https://orcid.org/0009-0008-1147-3918 , bekmezbayram107@gmail.com

[b.] https://orcid.org/0009-0002-3529-5374 , musabuniversite97@gmail.com

[c]. https://orcid.org/0000-0002-6311-7578 , msevkic@hotmail.com

[d.] https://orcid.org/0000-0001-5777-964X , mbdortbudak@gmail.com

✉**İlgili yazar:** musabuniversite97@gmail.com, +90 541 975 12 31

**Bu çalışma "MEETCON-WORK ULUSLARARASI GIDA, TARIM VE VETERİNER BİLİMLERİ KONGRESİ" kongresinde sözlü/özet bildiri olarak sunulmuştur.*

ÖZET

Hayvancılık sektörünün önemli bir parçası olan koyunlarda solunum sistemi hastalıkları ciddi bir problem olmaktadır. Yapılan bu çalışmada koyunlarda en sık gözlenen akciğer hastalıklarından bronkopnömonilerin patogenezinde oksidatif stres varlığının araştırılması amaçlandı. Bunun için bronkopnömonili koyun akciğer doku örneklerinde oksidatif stresin güncel biyomarkerlarından biri olan HSP (ısı şok protein) 27 ekspresyonu izlendi. Çalışma materyali farklı ırk, yaş ve cinsiyetteki 16 adet koyuna ait akciğer dokularından oluşmaktadır. Bronkopnömoniye (konsolidasyon) ilişkin makroskobik bulguları taşıyan akciğer dokularında histopatoloji için Hematoksilen-Eozin (HE) ve HSP 27 ekspresyonunu incelemek için immünohistokimyasal boyama yapıldı. Histopatolojik incelemede bronş/bronşiyol ve alveol lümenlerinde fibrinli yangı hücre eksudasyonu, solunum yolu epitellerinde dejenerasyon-nekroz ve vasküler değişiklikler kaydedildi. İmmünohistokimyasal incelemede ise bronş/bronşiyol ve alveol epitelleri ile yangı hücrelerinde HSP 27 ekspresyonu gözlendi. Yapılan bu çalışma sonucunda birçok hastalık patogenezinde etkili olan oksidatif stresin koyun bronkopnömonileri içinde geçerli olduğu, önemli bir oksdiatif stres biyobelirteci olan HSP 27 ekspreyonuyla ortaya konuldu. Ayrıca koyun bronkopnömonilerinde patogeneze katkı sağlamanın yanı sıra HSP 27 ‘nin hastalık tanısında potansiyel bir rol taşıyabileceği kanaatine varıldı.

Anahtar Kelimler: Isı şok protein, Koyun, Oksidatif stres, Patoloji, Pnömoni

1. INTRODUCTION

Pneumonia ranks among the primary health issues in sheep farming, which constitutes a significant portion of livestock production, and leads to serious economic losses. Pneumonia, which is the leading respiratory disease in sheep and is known as an inflammation of the lungs, is generally classified according to its pathogenesis and morphopathology into bronchopneumonia, interstitial pneumonia, embolic-metastatic pneumonia, and granulomatous pneumonia. Among these types of pneumonia, bronchopneumonia has the highest mortality rate and is observed quite frequently; within this category, it is further classified into fibrinous, catarrhal-purulent and aspiration bronchopneumonia. The causative agents of bronchopneumonia include various pyogenic bacteria, primarily *Pasteurella, Mannheimia* and *Mycoplasma species*, as well as *Streptococcus, Staphylococcus, Corynebacterium* and *Pseudomonas spp,* etc. (Abera and Mossie, 2023; Panciera and Confer, 2010). In addition to these, viral infections and various stress factors act as predisposing factors. The incidence of the disease increases in crowded conditions, where ventilation is inadequate or poor, during sudden changes in temperature, during transport, and in various states of immunosuppression. In the pathogenesis of the disease, infectious agents are directly inhaled via the aerosol route, or opportunistic pathogens become active in situations where immunity is suppressed and weaknesses develop in the respiratory system's defence barriers. These factors cause inflammation in the walls of the respiratory tract (bronchi, bronchioles and alveoli) and lead to the accumulation of various inflammatory products within the lumen. Clinical symptoms associated with this pathology (cough, breathing difficulties, etc.) are observed. On macroscopic examination, dark red and viscous consolidated areas are observed, predominantly in the cranial lobe. Depending on the severity of the disease, these may be fibrinous, necrotic or haemorrhagic in nature. Microscopically, degeneration, necrosis, hyperaemia, oedema and leukocyte infiltration are observed in the bronchial, bronchiolar and alveolar epithelia. Treatment involves the use of appropriate antibiotics and supportive measures. In the fight against the disease, vaccination and the improvement of environmental conditions are as important as treatment itself for prevention (Mohammed et al., 2022; Singh et al., 2017; Kumar et al., 2014).

Recent studies have shown that, as with many other diseases, oxidative stress plays a key role in the pathogenesis of pneumonia. Oxidative stress arises from an imbalance between reactive oxygen species and the antioxidant system. Immune system cells that become activated in response to pathogens causing pneumonia lead to an increase in free radicals and oxidative stress whilst fighting the infection (Sarkar and Sil, 2019; Bargagli et al., 2009). Heat shock proteins are produced to protect the cell from damage under conditions of oxidative stress. Among heat shock proteins, HSP 27 not only primarily ensures the stabilisation of proteins under oxidative stress but also contributes to antioxidant defence, apoptosis inhibition and cytoskeletal regulation. Due to these functions and, in particular, their increased expression under oxidative stress, these protein groups have recently also been evaluated as biomarkers of oxidative stress (Kalmar and Greensmith, 2009; Ganter et al., 2006).

The aim of this study was to investigate the possible presence of oxidative stress in the pathogenesis of bronchopneumonia in sheep. To this end, HSP 27 expression was examined using immunohistochemical methods in lung tissues from sheep histopathologically diagnosed with bronchopneumonia.

2. MATERIALS AND METHODS

2.1. Sample Collection and Tissue Processing

This study was conducted in accordance with the decision of the Harran University Local Ethics Committee for Animal Experiments dated 05 March 2026 and numbered 2026/002/07. The study materials consisted of 16 sheep lungs from animals of different breeds, ages and sexes, which exhibited macroscopic bronchopneumonia lesions. Lung tissue samples were fixed in 10% buffered formaldehyde for microscopic examination. Following fixation, the washed tissue samples underwent routine tissue processing (dehydration, cleaning and embedding). After tissue processing, tissue sections 5 µm thick were obtained from each paraffin block using a rotary microtome (Leica RM 2125, Germany).

2.2. Histopathological Examination

Tissue sections mounted on standard slides were stained with haematoxylin and eosin for histopathological examination. To this end, the tissues, which had been left in an oven for approximately one hour, were processed through a series of alcohols of decreasing concentration and distilled water for deparaffinisation and rehydration. The tissues stained with haematoxylin were then decolourised under running tap water and subsequently stained with eosin. The sections stained with haematoxylin and eosin were dehydrated with alcohol, cleared with xylene, and mounted on slides with Entallan. The HE-stained preparations were examined under a light microscope (Olympus BX 51, Japan) (Dörtbudak et al., 2022).

2.3. Immunohistochemical Examination

Tissue sections mounted on adhesive slides were incubated in an oven for approximately 1 hour, followed by deparaffinisation and rehydration using xylene-alcohol series and distilled water. The tissue sections were then incubated in 3% H_2O_2 for endogenous inactivation, washed with PBS, and subjected to three cycles of boiling and cooling in a retrieval solution to reveal the antigen. The tissues, washed with PBS, were marked with a PAP pen and incubated after applying a drop of protein blocking solution. Subsequently, the primary antibody (HSP 27) was applied to the tissues without washing and incubated overnight at +4°C. The tissues were washed again with PBS, and biotinylated secondary antibody was applied. A further wash with PBS was performed, followed by incubation with streptavidin-peroxidase conjugate. After a final wash with PBS, 3,3'-diaminobenzidine (DAB) chromogen was applied to the tissues to visualise the immune reaction; once the desired colour gradient was achieved, the sections were washed with distilled water. Following counterstaining with Mayer's haematoxylin, the tissue sections were passed through an alcohol-xylene series, mounted with Entellan, and covered with a coverslip. The immunohistochemically stained preparations were examined under a light microscope (Olympus BX 51, Japan) (Dörtbudak et al., 2022).

3. FINDINGS

3.1. Macroscopic Findings

Macroscopic examination revealed areas of consolidated/hepatised tissue in the lungs, generally in the cranial lobes, with an irregular distribution, distinct dark red colouration and a

firm consistency. Atelectasis and emphysema were observed in some specimens. The cross-sections of the lungs were mostly dry; in some specimens, thickening of the pleura and adhesion to surrounding tissues were observed (Figure 1).

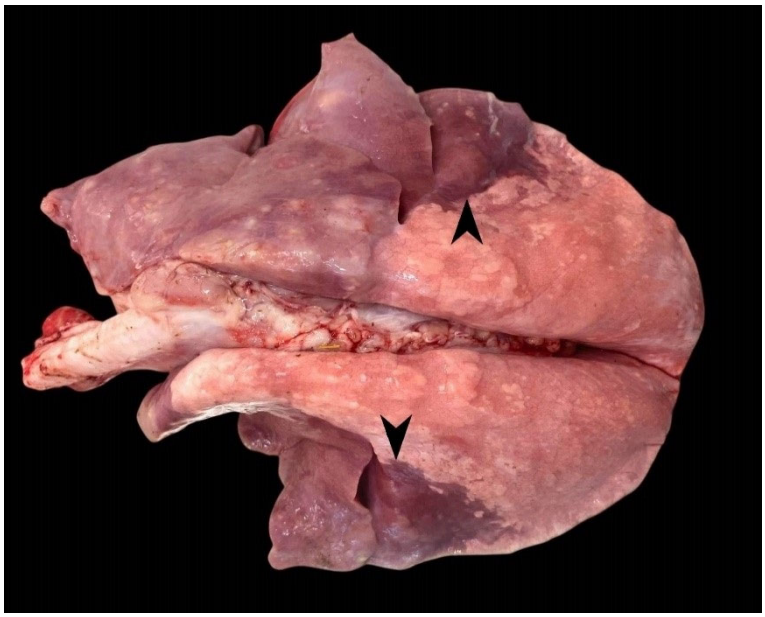

Figure 1. Sheep, Lung, Bronchopneumonia, Consolidated areas (arrowhead).

3.2. Histopathological Findings

Histopathological examination revealed findings consistent with bronchopneumonia, with the accumulation of exudate containing leukocytes and fibrin of varying concentrations observed in the lumina of the bronchi, bronchioles and alveoli. Desquamation was observed in the respiratory tract epithelium, accompanied by degenerative and necrotic changes. Vascular changes, including dilation, thrombosis and hyperaemia in the parenchymal vessels, were noted, and pulmonary fluid accumulation was observed in some alveoli (Figures 2, 3).

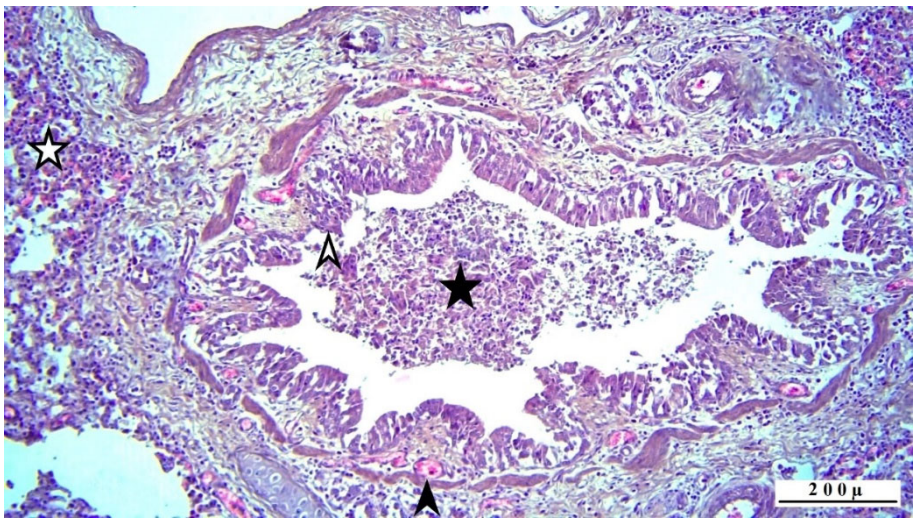

Figure 2. Sheep, Lung, HE, ×100, Scale bar: 200 µm. Serous-fibrinous exudate (star) containing desquamated epithelium and numerous leukocytes within the bronchial lumen; degenerative-necrotic lesions in bronchial epithelial cells (hollow arrowhead); peribronchial leukocyte infiltration (hollow star); hyperaemia in the vessels (arrowhead).

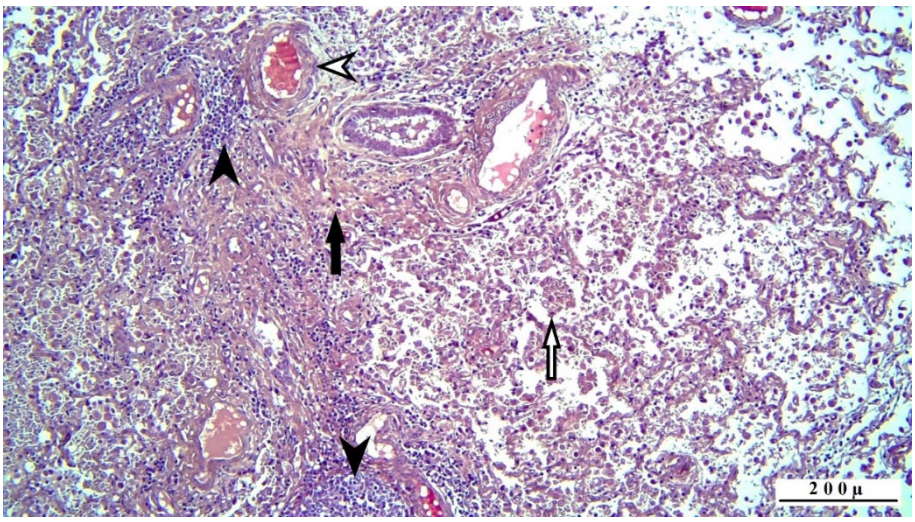

Figure 3. Sheep, Lung, HE, ×100, Scale bar: 200 µm. Exudate containing leukocytes in the alveolar lumina (hollow arrow), increased fibrin in the parenchyma (arrow) and inflammatory cell infiltration (arrowheads), and hyperaemia in the blood vessels (hollow arrowhead).

3.3. Immunohistochemical Findings

In the immunohistochemical analysis performed, high levels of HSP-27 expression indicative of oxidative stress were observed in the bronchial, bronchiolar and alveolar epithelia of the lung, as well as in inflammatory cells (Figure 4).

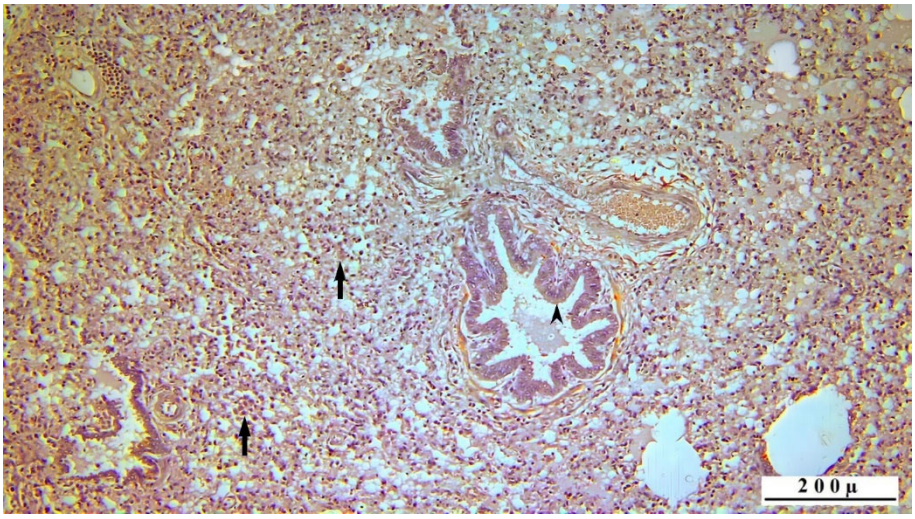

Figure 4. Sheep, Lung, HE, ×100, Scale bar: 200 µm. Marked expression of HSP-27 in bronchiolar and alveolar epithelial cells and some inflammatory cells (arrow).

4. DISCUSSION

Sheep hold a significant position in the livestock sector due to their high economic value, as they are the primary source of various animal products worldwide, particularly meat, milk and wool. Among the health problems affecting sheep, pneumonia ranks among the most common. In cases of bronchopneumonia—the most common and serious form—macroscopic examination has reported the presence of consolidated areas of varying firmness, often with irregular borders and appearing dark red or black-grey, particularly in the cranial lobes. Microscopically, degeneration and necrosis of the respiratory tract mucosal epithelium, inflammatory cell infiltration within the lumina, exudate containing fibrin, and various vascular abnormalities have been reported (Ali and Abdullah, 2024; Kumar et al., 2014). In this study, macroscopic and microscopic findings consistent with those of previous studies were observed.

Oxidative stress, which has been the subject of research for a long time and remains a topical issue, arises from an increase in free radicals during the body's normal metabolic processes, particularly as a result of energy production and various cellular activities. Oxidative stress is caused by an imbalance in the oxidation-reduction equilibrium, which arises either from a weakness in the antioxidant system or from an increase in reactive oxygen species. Free radicals present in excess of the threshold the organism can tolerate bind to important cellular components such as DNA, proteins and lipids, disrupting their structure and leading to cellular damage. Oxidative stress plays a role in the pathogenesis of many diseases, ranging from simple inflammation to complex processes such as cancer (Reddy, 2023; Rani et al., 2016). Bronchopneumonia is usually of bacterial aetiology and is characterised by extensive cellular destruction in the lung tissue, accompanied by a severe inflammatory reaction. The activation of inflammatory cells by bacteria and the resulting damage to host cells leads to oxidative stress. Various biomarkers are utilised to monitor oxidative stress (Celi, 2011; Bargagli et al., 2009). In current research, the use of heat shock proteins in studies of oxidative stress is becoming increasingly common. Heat shock proteins increase in response to stress with the aim of protecting the cell against damage. HSP 27, one of the heat shock proteins, works to repair protein damage caused by oxidative stress, halt cell death via apoptosis, and prevent the exacerbation of inflammation by regulating the immune response. Due to these properties of HSP 27, its expression is likely under conditions of oxidative stress (Bekmez, 2025; Ikwegbue et al., 2017; Parseghian et al., 2016). In this study, it was observed that HSP 27 expression was associated with the cellular damage and inflammatory changes resulting from bronchopneumonia.

Oxidative stress, given its key role, has long been the subject of numerous natural and experimental studies and continues to shed light on current research. There is a significant body of research demonstrating that oxidative stress plays a role in respiratory diseases in animals. El-Deeb et al. (2015) reported an increase in oxidative stress biomarkers in sheep with Pasteurella-induced pneumonia. Jarike et al. (2017) noted that oxidative stress biomarkers were elevated in the bronchoalveolar lavage of goats with pneumonia. In their study, Özbek and Özkan (2020) reported an increase in certain oxidative stress biomarkers in the blood of calves with enzootic pneumonia. Kırmızıgül et al. (2016) demonstrated that in sheep naturally infected with the pox virus, total oxidant capacity increased whilst total antioxidant capacity decreased, indicating that oxidative stress plays a role in the disease. Abdel-Saeed and Salem (2019) reported that antioxidant capacity decreased in sheep with verminous pneumonia, whilst

oxidation products increased, indicating the occurrence of oxidative stress. Shaukat et al. (2021) suggested that Staphylococcus aureus increases oxidative damage by suppressing oxidative stress genes in the lungs of cattle with pneumonia. In this study, consistent with the literature, an increase in oxidative stress was observed in the lungs of sheep with bronchopneumonia.

The presence of oxidative stress can be demonstrated using numerous biomarkers; indeed, in some studies, oxidative stress has been monitored using heat shock proteins, and their use for this purpose has gained considerable popularity in recent research. Gally et al. (2011) reported that heat shock proteins protect the lungs against mycoplasma infections, and that their absence leads to increased bacterial damage and prolonged inflammation. Hamel et al. (1997) reported that heat shock proteins trigger the immune response in streptococcal pneumonia and assist the organism in its fight against the bacteria. Dong et al. (2013) demonstrated that cigarette smoke induces oxidative stress in patients with COPD, as indicated by HSP 70 expression. Abdallah et al. (2025), in their study investigating the protective effects of rosuvastatin against lung damage in rats, assessed the impact of oxidative stress via heat shock proteins. Ünver et al. (2016) found that HSP 27 expression was significantly elevated in COPD patients and suggested that HSP 27 could serve as a diagnostic biomarker for COPD. Marendino et al. (2002) reported increased HSP 27 expression in the bronchial epithelium of patients with chronic asthma. In this study, consistent with previous findings, the presence of oxidative stress in the lungs of sheep with bronchopneumonia was demonstrated by an increase in HSP 27 expression.

A review of the literature revealed no studies in ruminants where oxidative stress in the lungs of sheep with bronchopneumonia was monitored via HSP 27 expression, as was done in this study. However, there are a few studies in which stress-induced oxidative damage in goats was investigated via heat shock protein expression. Zheng et al. (2021) reported that transport stress caused damage to the respiratory tract in goats, with increased HSP 70 expression in the trachea and bronchi. Hu et al. (2020) demonstrated the presence of oxidative stress in various internal organs, including the lungs, in goats under transport stress through the expression of HSP 27, HSP 70 and HSP 90. In this study, consistent with the existing literature, the increase in oxidative stress in bronchopneumonia was assessed via HSP 27 expression.

5. CONCLUSION

In conclusion, this study demonstrated that oxidative stress occurs in bronchopneumonia, a significant health issue in sheep. Oxidative stress, which plays a role in the pathogenesis of the disease, was observed through increased HSP 27 expression. Furthermore, it was established that HSP 27 not only contributes to understanding the disease process but also plays a potential role in diagnosis and is of importance in the development of treatment strategies.

Conflicts of Interest

The authors declared no conflicts of interest.

Ethics Statement

The study was approved by the Harran University Animal Experiments Local Ethics Committee (Protocol Number: 2026/002/07).

Data Availability Statement

All data and materials of the study are available in contact with the corresponding author.

REFERENCES

Abdallah, H. H., Abd El-Fattah, E. E., Salah, N. A., & El-Khawaga, O. Y. (2025). Rosuvastatin ameliorates chemically induced acute lung injury in rats by targeting ferroptosis, heat shock protein B1, and inflammation. *Naunyn-Schmiedeberg's Archives of Pharmacology*, *398*(2), 1883-1894.

Abdel-Saeed H and Salem NY, (2019). Evaluation of total antioxidant capacity, malondialdehyde, catalase, proteins, zinc, copper and IgE response in ovine verminous pneumonia. Inter J Vet Sci, 8(4): 255-258.

Abera, D., & Mossie, T. (2023). A review on pneumonic pasteurellosis in small ruminants. *Journal of Applied Animal Research*, *51*(1), 1-10.

Ali, B. A., & Abdullah, M. A. (2024). Pathologıcal Study Of Pnumonıa In Sheep And Goat In Abttoıtr At Duhok Provınce. *Iraqi Journal of Agricultural Sciences*, *55*(4), 1367-1380.

Bargagli, E., Olivieri, C., Bennett, D., Prasse, A., Muller-Quernheim, J., & Rottoli, P. (2009). Oxidative stress in the pathogenesis of diffuse lung diseases: a review. *Respiratory medicine*, *103*(9), 1245-1256.

Bekmez, B. (2025). The Role of Heat Shock Proteins in Oxidative Stress. *Journal of Academic Union Association*, *1*(1), p. 36-50.

Celi, P. (2011). Biomarkers of oxidative stress in ruminant medicine. *Immunopharmacology and immunotoxicology*, *33*(2), 233-240.

Dong, J., Guo, L., Liao, Z., Zhang, M., Zhang, M., Wang, T., ... & Wen, F. (2013). Increased expression of heat shock protein 70 in chronic obstructive pulmonary disease. *International immunopharmacology*, *17*(3), 885-893.

Dörtbudak, M. B., Saglam, Y. S., Yildirim, S., & Timurkan, M. Ö. (2022). Examination of adenovirus with molecular and pathological methods in cases of ovine pneumonia. RevMVZ Cordoba. 2022; 27(Supl), e2738.

El-Deeb, W. M., & Tharwat, M. (2015). Lipoproteins profile, acute phase proteins, proinflammatory cytokines and oxidative stress biomarkers in sheep with pneumonic pasteurellosis. *Comparative Clinical Pathology*, *24*(3), 581-588.

Gally, F., Minor, M. N., Smith, S. K., Case, S. R., & Chu, H. W. (2011). Heat shock factor 1 protects against lung mycoplasma pneumoniae infection in mice. *Journal of Innate Immunity*, *4*(1), 59-68.

Ganter, M. T., Ware, L. B., Howard, M., Roux, J., Gartland, B., Matthay, M. A., ... & Pittet, J. F. (2006). Extracellular heat shock protein 72 is a marker of the stress protein response in acute lung injury. *American Journal of Physiology-Lung Cellular and Molecular Physiology*, *291*(3), L354-L361.

Hamel, J., Martin, D., & Brodeur, B. B. (1997). Heat shock response ofStreptococcus pneumoniae: identification of immunoreactive stress proteins. *Microbial pathogenesis*, *23*(1), 11-21.

Hu, W., Fang, M., Yang, Y., Ye, T., Liu, B., & Zheng, W. (2020). Detection of heat shock protein 27, 70, 90 expressions in primary parenchymatous organs of goats after transport stress by real-time PCR and ELISA. *Veterinary medicine and science*, *6*(4), 788-795.

Ikwegbue, P. C., Masamba, P., Oyinloye, B. E., & Kappo, A. P. (2017). Roles of heat shock proteins in apoptosis, oxidative stress, human inflammatory diseases, and cancer. *Pharmaceuticals*, *11*(1), 2.

Jarikre, T. A., Ohore, G. O., Oyagbemi, A. A., & Emikpe, B. O. (2017). Evaluation of oxidative stress in caprine bronchoalveolar lavage fluid of pneumonic and normal lungs. *International journal of veterinary science and medicine*, *5*(2), 143-147.

Kalmar, B., & Greensmith, L. (2009). Induction of heat shock proteins for protection against oxidative stress. *Advanced drug delivery reviews*, *61*(4), 310-318.

Kirmizigul AH, Ogun M, Ozen H, Erkilic EE, Gokce E, Karaman M and Kukurt A, (2016). Oxidative stress and total sialic acid levels in sheep naturally infected with pox virus. Pak Vet J, 36(3): 312-315.

Kumar, M. A., Kumar, R., Varshney, K. C., Nair, M. G., Lakkawar, A. W., Sridhar, B. G., & Palanivelu, M. (2014). Pathomorphological studies of lung lesions in sheep. *Indian Journal of Veterinary Pathology*, *38*(2), 75.

Merendino, A. M., Paul, C., Vignola, A. M., Costa, M. A., Melis, M., Chiappara, G., ... & Arrigo, A. P. (2002). Heat shock protein-27 protects human bronchial epithelial cells against oxidative stress–mediated apoptosis: possible implication in asthma. *Cell stress & chaperones*, *7*(3), 269.

Mohammed, Z. M., Ibrahim, W. M., & Abdalla, I. O. (2022). Pneumonia in slaughtered sheep in Libya: gross and histopathological findings. *European Journal of Veterinary Medicine*, *2*(1), 4-9.

Özbek, M., & Özkan, C. (2020). Oxidative stress in calves with enzootic pneumonia. *Turkish Journal of Veterinary & Animal Sciences*, *44*(6), 1299-1305.

Panciera, R. J., & Confer, A. W. (2010). Pathogenesis and pathology of bovine pneumonia. *The Veterinary Clinics of North America. Food Animal Practice*, *26*(2), 191.

Parseghian, M. H., Hobson, S. T., & Richieri, R. A. (2016). Targeted heat shock protein 72 for pulmonary cytoprotection. *Annals of the New York Academy of Sciences*, *1374*(1), 78-85

Rani, V., Deep, G., Singh, R. K., Palle, K., & Yadav, U. C. (2016). Oxidative stress and metabolic disorders: Pathogenesis and therapeutic strategies. *Life sciences*, *148*, 183-193.

Reddy, V. P. (2023). Oxidative stress in health and disease. *Biomedicines*, *11*(11), 2925.

Sarkar, K., & Sil, P. C. (2019). Infectious lung diseases and endogenous oxidative stress. In *Oxidative Stress in Lung Diseases: Volume 1* (pp. 125-148). Singapore: Springer Singapore.

Shaukat, A., Hanif, S., Shaukat, I., Shukat, R., Rajput, S. A., Jiang, K., ... & Deng, G. (2021). Upregulated-gene expression of pro-inflammatory cytokines, oxidative stress and apoptotic markers through inflammatory, oxidative and apoptosis mediated signaling pathways in Bovine Pneumonia. *Microbial Pathogenesis*, *155*, 104935.

Singh, R., Kumar, P., Sahoo, M., Bind, R. B., Kumar, M. A., Das, T., ... & Singh, R. (2017). Spontaneously occurring lung lesions in sheep and goats. *Indian J. Vet. Pathol*, *4*(1), 18-24.

Ünver, R., Deveci, F., Kırkıl, G., Telo, S., Kaman, D., & Kuluöztürk, M. (2016). Serum heat shock protein levels and the relationship of heat shock proteins with various parameters in chronic obstructive pulmonary disease patients. *Turkish Thoracic Journal*, *17*(4), 153.

Zheng, W., Liu, B., Hu, W., & Cui, Y. (2021). Effects of transport stress on pathological injury and main heat shock protein expression in the respiratory system of goats. *Journal of animal physiology and animal nutrition*, *105*(1), 1-13.